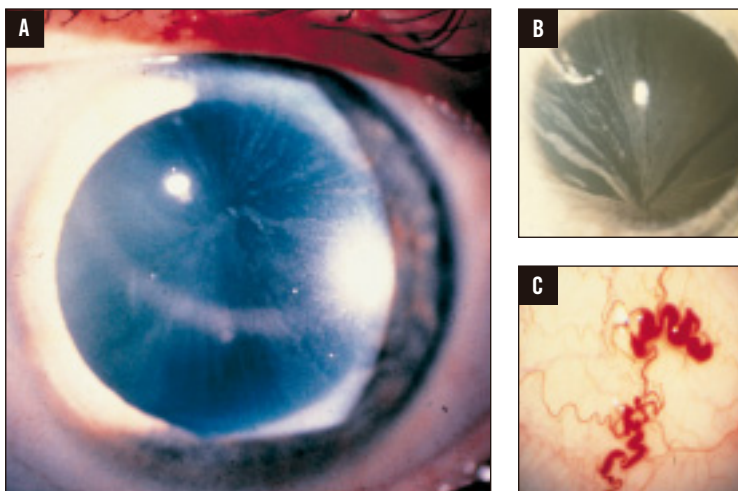


If you see a patient with corneal opacities  
It could be Fabry disease



**Panels A and B:** Distinctive corneal opacity (corneal verticillata or vortex keratopathy) in Fabry disease. Note the whorl-like corneal rays emanating from a single vertex like the spokes of a wheel. Panel B image used with permission, RL Abbott, MD. **Panel C:** Conjunctival involvement in Fabry disease. Note the sausage-like and markedly dilated vessels. These signs of Fabry disease typically do not affect vision.

**Eye care professionals have the opportunity to identify patients with this progressive, often life-threatening disease.**

**In addition to corneal opacities, patients with Fabry disease may present with:**

- Posterior capsular cataracts with whitish spokelike deposits of granular material (Fabry cataract)
- Aneurysmal dilatation of thin-walled venules on the bulbar conjunctiva
- Mild-to-marked tortuosity and angulation of the retinal vessels

**Other manifestations include:**

- Progressive and/or unexplained chronic kidney disease
- Premature cardiac disease and/or stroke
- “Burning” pain in the hands and feet
- Heat/cold and exercise intolerance
- Impaired sweating
- Angiokeratomas (reddish-purple skin lesions that do not blanch with pressure)

**While Fabry disease is rare, it may be more common within a Fabry family.**

# Fabry disease

Progressive. Destructive. Life-threatening.



## FABRY DISEASE PROFILE

Fabry disease is an often life-threatening, panethnic, and heterogeneous inherited disorder caused by a lysosomal enzyme (alpha-galactosidase A) deficiency. The resulting progressive accumulation of globotriaosylceramide (GL-3) in the vasculature and other cell types or tissues eventually leads to major organ system damage including renal insufficiency, cardiac disease, and premature stroke.

## DISEASE RISK IN FAMILIES

- An X-linked disorder, Fabry disease is carried on the X chromosome.
- Males with the disease pass the defective gene on to all of their daughters and none of their sons.
- Females have a 50% chance with each pregnancy of passing the defective gene to both their sons and daughters.
- Unlike many other X-linked diseases, females can have varying degrees of disease manifestations.

## DIAGNOSIS

- Although Fabry disease usually presents in childhood, the disease often goes unrecognized by physicians until adulthood, when the underlying pathology is advanced.
- Delayed diagnosis may be the result of disease under-recognition and/or symptoms being mistaken for those of other disorders, such as rheumatoid or juvenile arthritis, rheumatic fever, erythromelalgia, multiple sclerosis, or lupus.
- Clinical diagnosis is based upon presentation of signs and symptoms.
- Diagnosis is confirmed in males by enzyme assay (blood test) detecting low or absent levels of alpha-galactosidase A (alpha-GAL), or in females by mutation linkage analysis (blood test).

## TREATMENT

Treatment is available for Fabry disease. Patients should be referred to a geneticist for testing and further intervention.

## LEARN MORE

Visit [www.fabrycommunity.com](http://www.fabrycommunity.com) for more information on Fabry disease or call Genzyme Medical Information at 800-745-4447 or 617-768-9000.

**Early diagnosis and intervention are key—eye care professionals can play a role.**

genzyme